2009 CSAWC
San Antonio, TExas

Gleaves, Jim, MD. Surgeon, Rush Hospital, Meridian, Mississisppi

Eldridge, Kim, RN, Rush Hospital, Merrdian, Mississippi

Treatment of a severe Fournier's necrotizing fasciitis involving the scrotum and volar penile skin associated with a malfunctioning penile prosthesis affixed in the erect position with a delicate split thickness skin graft anchored with a powder dressing

Objectives

Understand the significant complications following a Fournier's necrotizing fasciitis of a male perineum and its treatment with a meshed split thickness skin graft on the scrotum and volar surface of a penis which was incidentally associated with a damaged penile implant.

Be exposed to the delicate nature of graft suturing and affixation when attempting to apply a meshed split thickness skin graft in one setting to the penile and scrotal skin.

Introduction

Simple geometry reveals that any one singular infintesimal point on the scrotal surfaces of two spheroidal masses can be assoiciated with only one plane. A spheroid surface has a multiplicity of planes throughout its surface extending to the periphery of the graft. It is very difficult to affix the graft without multiple sutures and/or clips throughout the grafts surface and not just at the periphery of the graft. This type of procedure typically requires multiple grafting procedures.

Methods

This case study presents the treatment of a 71 year old diabetic, African American male, who had a penile implant which became damaged and was malfunctioning with his penis in a permanent erect state ("bent" superiorly in the standard 90 degrees perpendicular to the patients body frame in a "functional position"). The damaged penile implant complicated the treatment after onset of the infection that had developed six days earlier, as Fournier's necrotizing fasciitis with severe systemic sepsis. This necrotizing faciitis involved the entire scrotum traveling along the volar surface of the penis toward the base of the glands. Immediate initial treatment included: broad spectrum antibiotics, treatment with hyperbarics prior to the urologist taking the patient to the operating room where under general anesthesia the entire scrotal skin was removed up to the base of and including that of the penis. He was treated for approximately two weeks with intravenous antibiotics, aggressive local care, and hyperbarics for two weeks prior to grafting. Grafting the scrotum is particularly difficult due to its shape and it usually requires multiple trips to the operating room to get adequate coverage due to the double spheroidal structure of the scrotum. The skin on the base of the penis is essentially perpendicular in relation to skin found on the scrotum. This tissue is quite delicate; pain and sensation can be extraordinarily excruciating and exceptionally miserable for the patient. One large graft (400 to 500 cm²) was applied and this was meshed 3:1, sutured at the periphery where the scrotum had reached the base of the thighs and perineal area posteriorly and onto the penis using absorbable vicryl stitches; fewer than normal were used due to the Powder Wound Dressing* (PWD) fixation. No additional stitches were used in the bed of the graft nor in the area where an additional piece of graft was placed to cover the volar penile skin. The graft was covered with a PWD and aggregated with saline mist, which then affixed and anchored the graft to the underlying deep scrotal and penile wound surface. A light secondary dressing of 4x4's and net gynecology underwear was applied but no significant affixation to the secondary dressing was necessary. On one occasion in the following two weeks an additional dose of PWD was applied and aggregated again with saline.

Gently Debrided Wound

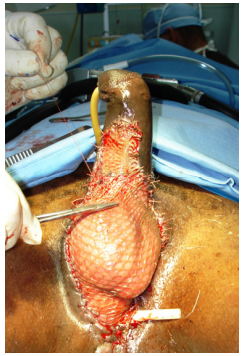

Application of Mesh Graft and Suturing

Graft in place with Application of Powder as Primary Graft Fixation

Gentle Spreading of Powder Dressing Over Graft and Tissue Surface

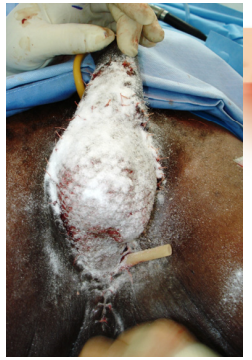

Powder Dressing in Place with Hydration and Aggregation Occurring

Day 5: Dressing Change. Powder Dressing has been removed from the scrotum. Some of the intact dressing and wound veil used to cover the primary dressing is visible on the dorsal skin of the penis.

Day 12: Primary dressing left in place with tissue ingrowth visible at graft interstices.

Day 15: Graft in place with substantial ingrowth of new skin. Primary dressing no longer present.

Day 19: Graft at nearly 100% take with new skin through all interstitial spaces.

6 Weeks Post Operative: Complete take of graft with excellent cosmesis.

Findings

The wound continued to show ongoing improvement following the grafting procedure. The skin graft began to turn obviously pink over its entire bed covering the scrotum and penis by the third day and it could be seen through the light layer of PWD as it was translucent. By the end of 14 days not only did the entire graft had a 100% take of all skin that was applied but the interstitial spaces between the webs were epithelialized. The graft remained anchored and "took" completely showing total epithelialization by the fourth week. It should be added that the PWD was also used on the donor site without a second dressing. The donor site was 24 cm x 8 cm. The donor site produced no pain post operation.

Conclusions

This case demonstrates that meshed STSG can be held in position and anchored to the bed with PWD that reconstitute themselves into a congealed "superstructure". Numerous areas on the graft that would have normally been sutured, were not sutured nor clipped at all, thusly decreasing pain. For the novel and unusual wound, dressing and treatment of the site following surgery requires delicate care and obviously in this case, minimal dressing changes and handling markedly improving the patients comfort. It also shows the scrotum which is a very difficult area to graft particularly when associated with a penile skin loss injury can be quite well handled with a PWD to help affix the graft to the wound bed. This is consistent with other studies where we have been successful in areas that are planar and flat or gently curved to be able to completely affix a skin graft without any other fixation including clips or sutures.
A secondary conclusion was that donor sites have very little to no pain when treated with the PWD.

The complications following a Fournier's necrotizing fasciitis of a male perineum and the treatment with a meshed STSG on the scrotum and volar surface of the penis associated with a damaged penile implant can be an exceptional challenge to both the patient and the surgeon.

This case study, reveals that delicate grafting of surfaces with complex geometry can be accomplished by fixation of a graft to a well perineum using a powder wound dressing. There was less pain as a minimal number of sutures were placed and dressing changes were minimized. There were no dressing changes for the donor site and powder wound dressing (PWD) was used as a the dressing, which also relieved pain in the donor site.

References

Fitzgerald, R, Bharara, M, Mills, J, Armstrong, DG (2009); "Use of a Nanoflex powder dressing for a wound management following debridement for necrotizing in the diabetic foot" International Wound Journal 6(2); 133-139.

Eldridge, K. E.; Gleaves, J. M. (2009) "A new treatment in Mesh Skin Graft Procedures Using a Novel Powder Dressing for Clipless, Sutureless, Skin Graft Fixation" Poster Presentation, Society for Advanced Woundcare Meeting, Grapevine, Texas.

*Altrazeal™ Transforming Powder Dressing