Comparison in Management of Large, Open Combat Wounds in Service Personnel Using Negative Pressure Wound Therapy as Standard of Care and a Novel Powder Dressing

Barry D. Martin, MD, FACS, LTC(P), Medical Corps, USA
Chief, Integrated Plastic Surgery Service, Consultant to The Surgeon General in Plastic Surgery
Walter Reed Army Medical Center/ National Naval Medical Center Washington, DC/ Bethesda, MD

2009 SAWC Meeting
Grapevine, Texas

Home of Warrior Care
WALTER REED
ARMY MEDICAL CENTER

Introduction

Combat trauma produces wound patterns that are seldom observed in civilian hospitals and require complicated surgery and post-operative care. The damage created by explosive devices depends on a number of factors, including the type of explosive, and the environment within which the detonation takes place. Injuries are dependent on the power of the explosion, the proximity of the casualty to the explosion and the environment (open or confined). When the energy of an explosion is directed towards tissue it creates a wound that is catastrophic to deep tissue and that will require surgical reconstruction until fully healed. In addition, this type of wound is universally accompanied by penetrating shrapnel which carries bacteria deep into the wound. Currently blast wounds in Uniformed Services Hospitals are managed uniformly with negative pressure wound therapy (NPWT), which is used to stabilize the wound, remove bacteria from tissue, and ultimately provide a well-vascularized granulation bed suitable for subsequent grafting.

This set of cases details the post-operative management of three combat trauma wounds where a combination of NPWT and a novel powder dressing are used to achieve closure.

Saphenous artery fasciocutaneous flap coverage of a posterior popliteal wound with exposed nerve from a rocket-propelled grenade attack in Iraq.
Patient is a healthy 38 year old male with a concominant closed head injury.
Initial treatment was serial debridements with VAC coverage for ten days. The procedure was complicated by superficial skin necrosis which was managed by debridement and NPWT (4 days) followed by skin grafting covered with the powder dressing for 10 days.

Patient is now five months post-injury with a healed wound pending secondary nerve grafting.

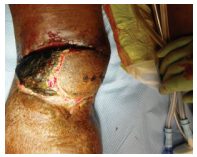

Partial Flap loss
Pre-debridement

Post-debridement

2 weeks post grafting

Latissimus dorsi myocutaneous free-tissue transfer with large skin grafts to the wound 2 weeks following injury.
Patient is a 26 year old male healthy medic who suffered an open fracture of his anterior knee/thigh with large soft tissue loss.
Initial pre-flap management was serial debridement and VAC dressings. Post-flap dressings were NPWT as a bolster over the recipient graft sites and the powder dressing to his skin-graft donor sites and the recipient site following removal of NPWT. The graft sites required two additional applications of the powder dressing until complete re-epithelialization occurred at 3 weeks following flap procedure.

Patient is now 3 months post-op with a healed wound and ambulatory. He is also currently being treated by osseous distraction/lengthening of his femur fracture. Patient will require subsequent tendon grafting to improve knee extension power.

Initial Wound following debridement
NPWT, and external distractor

Flap inset with
Surrounding Skin Grafts

Three weeks post-op

Anterolateral thigh free-tissue transfer and large skin grafting five months ago.
Patient is a 22 year old male healthy infantry soldier who suffered an IED blast injury to his lower leg and ankle with an open ankle fracture, exposed tendons and a segmental nerve deficit. The other injury was a traumatic below-knee amputation of the opposite leg.
Initial management was serial debridement, NPWTfor 10 days prior to free flap.
Post-op management was NPWT bolster over skin grafted areas with transition to powder dressing for two weeks (three applications required).

Patient is completely healed, ambulatory and awaiting nerve grafting

Initial wound following
debridement, and NPWT,

One week post free flap, powder
wound dressing in place

Three Weeks
Post Grafting

Discussion

Complicated trauma cases involve detailed assessment and planning prior to reconstructive surgery. The choice of techniques for post-operative management is critical and can often be overlooked after the surgical procedure is completed. For trauma cases involving reconstructive surgery with flaps or skin grafts, the conventional choice is NPWT or bolster dressing(s). These techniques are viable and functional options. A novel powder dressing was evaluated as a choice for covering and protecting a flap or mesh STSG after the application of NPWT. This technique was evaluated to determine if it was possible to transition from NPWT to the use of a unique powder dressing for closure. The data set is limited, however, the powder dressing does appear to cover and protect a wound during closure with dressing changes at intervals between 3 and 7 days.

Conclusions

It is possible to transition from NPWT to the use of a novel powder dressing in post operative care of combat trauma cases involving reconstructive surgery. Further studies as to the timing of the transition would benefit the development of best clinical practice for the use of this novel dressing.