A Novel Pre-Grafting Wound Management Technique to Promote Granulation in Complex Painful Wounds

Jonathan M. Saxe, MDMAR, MBA, FACS; Ascension St. Vincent Hospital, Indianapolis, IN, USA; Mounir Mabrouk, MD; Alexandria University, Egypt | WOCNext 2022 Meeting, Fort Worth, TX, June 5-8, 2022

BACKGROUND

Skin grafting (SG) is used to provide coverage in both acute and chronic wound settings. Preparation of the wound bed with development of granulation tissue is vital for graft success.[1] Traditional standard of care (SOC) wound management principles involve debriding the wound followed by negative pressure wound therapy (NPWT), bolstering or conventional dressing applications to accelerate wound healing prior to grafting.[2] Current SOC is limited in complex painful wounds. NPWT deployment and application is often difficult and painful.[3] Pain is also a significant issue often associated with repeated wound dressing changes.

METHODOLOGY & MATERIAL

Three case studies incorporating treatment with Transforming Powder Dressing (TPD) to promote granulation in patients with complex wounds are reviewed. In each case, patients had extensive wounds with high levels of reported pain. Prior treatment in all cases failed to progress wounds to the stage to permit grafting. Cases reviewed include a large abdominal wound resultant of an automobile accident, complex wounds associated with uncontrolled chronic vasculitis, and an improvised explosive device (IED) accident. TPD was introduced to facilitate and promote granulation and allow grafting.

TPD is comprised primarily of biocompatible polymers. Upon hydration with saline, TPD granules aggregate to form a moist, oxygen-permeable matrix that protects the wound from contamination while helping to manage excess exudate through vapor transpiration. Once applied, TPD may be left in place for up to 30 days and additional powder may be added ("topped off") as needed without requiring primary dressing changes. Simple secondary dressings may be used in areas of high exudation or friction. TPD dries and flakes off as the wound heals.

RESULTS

PATIENT 1: 40 y/o female with large complex abdominal wound resultant of car accident
Challenge: NPWT could not be placed due to risk of fistula
TPD Treatment: TPD applied to wound with foam for excess exudate absorption
Outcomes Post-TPD Treatment:

- Wound was ready for grafting by Day 18

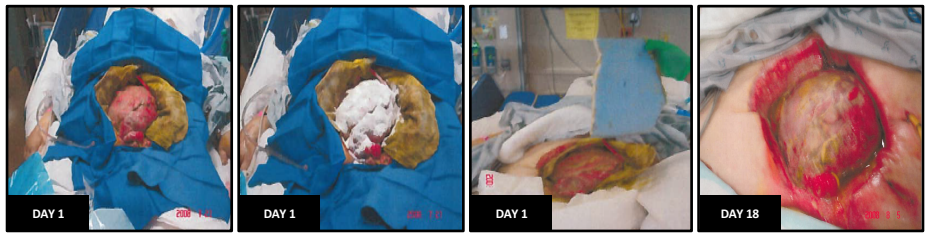

PATIENT 2: 42 y/o male with non-healing progressive venous ulcer, uncontrolled vasculitis, infection history, necrosis, exposed bone
Challenge: High pain score (9/10), failed SOC treatment
Treatment: TPD 2x/week in the first week and 1x/week after
Outcomes Post-TPD Treatment:

- Significant reduction in pain
- Granulation tissue covered bone and patient was grafted
- Avoided amputation

PATIENT 3: 40-year-old male with a 25cm x 25cm x 5cm IED blast wound due to consumer firework accident (M-80)
Challenge: NPWT was discontinued due to patient pain, porcine matrix failed to stimulate granulation
Treatment: TPD applied weekly
Outcomes Post-TPD Treatment:

- Wound depth reduced from 5cm to 2cm by day 7
- Wound was ready for grafting by day 18

CONCLUSION

A marked acceleration in granulation was observed in all three cases. Patients reported reduced pain and the frequency of dressing changes were also reduced relative to SOC. No adverse events were reported. Based on the clinical observations and outcomes, we conclude that TPD presents a safe and effective modality for preparing complex painful wounds for successful grafting.

REFERENCES

1. Kirsner, R. S., Bernstein, B., Bhatia, A., Lantis, J., Le, L., Lincoln, K., Liu, P., Rodgers, L., Shaw, M., & Young, D. (2015). Clinical Experience and Best Practices Using Epidermal Skin Grafts on Wounds. Wounds : a compendium of clinical research and practice, 27(11), 282–292.
2. Harries, R. L., Bosanquet, D. C., & Harding, K. G. (2016). Wound bed preparation: TIME for an update. International wound journal, 13 Suppl 3(Suppl 3), 8–14.
3. Upton, D., & Andrews, A. (2015). Pain and trauma in negative pressure wound therapy: a review. International wound journal, 12(1), 100–105.

Acknowledgements: This poster was developed and presented in collaboration with ULURU Inc.; Jonathan M. Saxe, MDMAR, MBA, FACS currently serves as Medical Director for ULURU Inc.