

# A TRANSFORMING POWDER DRESSING (TPD) TO IMPROVE HEALING OF DEEP PARTIAL THICKNESS BURN WOUNDS

Shanmugasundaram Natesan, PhD<sup>1,2</sup>; David A Larson, MS<sup>2</sup>; Sean Christy, BS<sup>2</sup>; Robert J Christy, PhD<sup>3</sup>

<sup>1</sup>Altrazeal Life Sciences Inc., 4410 Beltway Drive, Addison, TX 75001 | <sup>2</sup>The Metis Foundation, 84 NE Interstate 410 Loop, Suite 325, San Antonio, TX 78216

<sup>3</sup>University of Texas Health Science Center San Antonio, 7703 Floyd Curl Drive, San Antonio, TX 78229

Symposium on Advanced Wound Care | April 26 – 30, 2023 | National Harbor, MD

## INTRODUCTION

Burn wound care is a major socio-economic problem in the United States (1-2). According to the American Burn Association's National Burn Repository, approximately half a million people in the United States are severely burned each year (3). The current standard of care (SOC) for burn wound management is application of gauze and/or antimicrobial treatments (4). Unfortunately, these limited options to treat acute burn wounds do not address common comorbidities seen in burn patients associated with frequent dressing changes, infection prevention, and tissue preservation (5). Therefore, there is a requirement to optimize burn wound treatment using a 'temporizing', yet cost-effective wound dressing. To address this problem, we evaluated a commercially available, transforming powder dressing (TPD) that improves wound healing and can stay on a wound for extended periods of time (up to 30 days).

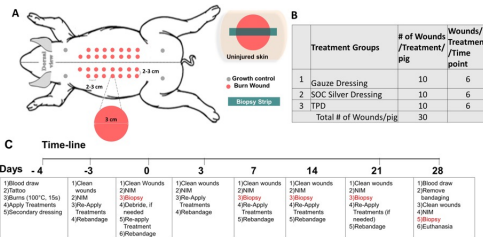
## OBJECTIVES AND HYPOTHESIS

*The objective of this project was to evaluate the efficacy of TPD wound dressing using a porcine deep partial thickness burn wound model.*

*Hypothesis: Early initial treatment of acute burn wounds with TPD will reduce time for complete wound closure and improve healing outcomes.*

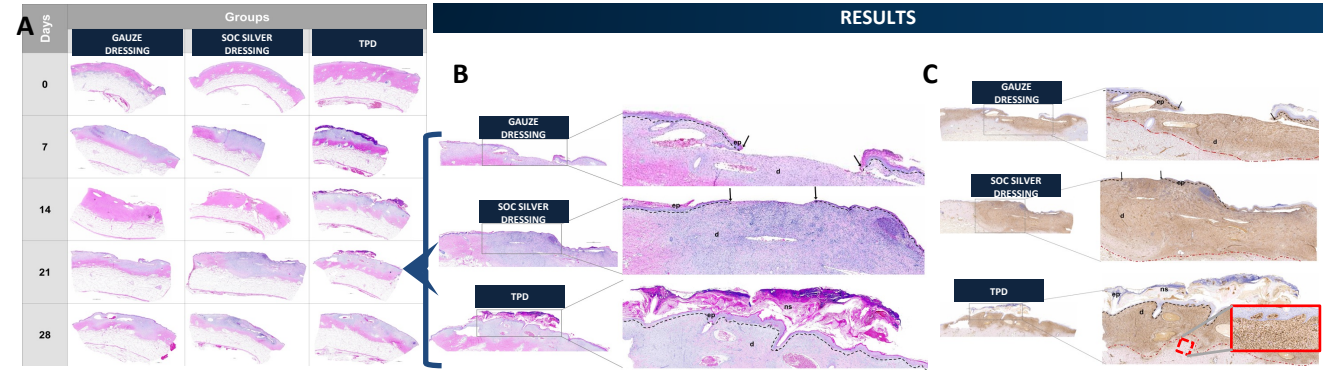
## METHODS

Deep partial thickness (DPT) 3cm diameter burn wounds were created on the dorsum of anesthetized Yorkshire pigs (n=3, 30 wounds/pig). Three treatment groups (TPD, a silver-based dressing and gauze) were randomized across three pigs (10 wounds/pig/treatment). Treatments were applied one-hour post-injury, reapplied on days 7 and 14, and redressed as needed. Wound re-epithelialization and contraction were measured over time using a 3D imaging system and a digital camera.



**Figure 1:** TPD evaluation with a 3cm diameter porcine DPT burn model:  
**A:** Experimental design with 3cm diameter deep partial porcine burns and biopsies  
**B:** Treatment groups  
**C:** Experimental timeline

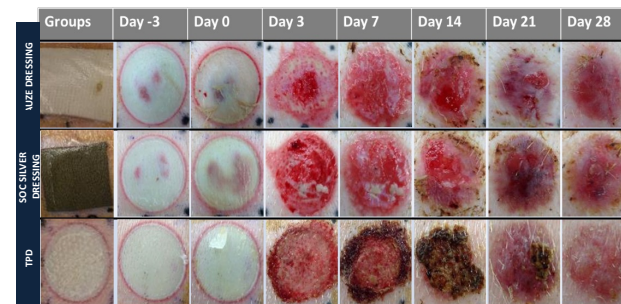
On days 0, 7, 14, 21 and 28, biopsy strips were harvested through the center of the wound bed histological analysis. Hematoxylin and Eosin (H&E) staining was used to observe re-epithelialization, and the epithelial gap in different groups. Further, slides were stained for necrosis and viability analyses using vimentin antibodies. A biotinylated avidin/horseradish peroxidase enzyme was used as secondary antibody and detected using a DAB (3,3' Diaminobenzidine) substrate kit.



**Figure 2:** (A) Representative H&E images of the entire biopsy strip spanning wound bed with adjacent normal skin, harvested at different post-treatment days (scale bars = 2mm). (B) Representative H&E images of biopsy samples harvested at day 21. Images on left are the entire biopsy strip (scale bars = 2mm). The area indicated by the black box is the enlarged image on the right (100 μm). (C) Vimentin stained biopsy section on day 21 confirms complete re-epithelialization of TPD treated groups. The tissue that is stained brown above the red dotted line are positive for vimentin. The image inset within the red box is a magnified section showing cell-associated vimentin indicating re-organizing dermis. Black arrows in figure 2B and 2C indicate the re-epithelializing wound edges present on both sides of the tissue section. ep = newly formed epidermis; d = dermis; ns = residual necrotic slough.

## DISCUSSION

- TPD adhered to the burn wound bed after initial application on day 0 and flaked-off as the wound healed (days 7 & 14) with complete re-epithelialization by day 21
- H&E stained biopsy sections (day 21) confirmed complete re-epithelialization of wounds treated with TPD, whereas wounds using gauze and silver-based dressings still had open wound areas. For the TPD treated wounds, the dermal layer of the wounds had a more organized collagen structure
- The quality of healing was monitored using vimentin stained tissue sections. Day 21 sections indicated vimentin in TPD treated wounds conferred with proliferating dermal cells, illustrating the formation of an organized cytoskeletal network, critical to providing cell structure and resulting in re-organized wound dermis
- In summary, TPD presented an easy-to-use dressing that created a favorable microenvironment that improved wound healing with reduced frequency of primary dressing changes relative to SOC therapies



**Figure 3:** Representative time-course digital images of DPT wounds treated with gauze dressing, SOC silver dressing and TPD.

## REFERENCES & ACKNOWLEDGEMENTS

[1] Kagan RJ et al, Surgical Management of the Burn Wound and use of skin substitutes. American Burn Association White Paper, 2009. [2] Jones T et al., Effect of graft bed on long-term functional results of extremity skin grafts. J Burn Care Rehabil. 1998;9(1):72-4. [3] American Burn Association, Burn incidence and Treatment in the United States: 2016. [4] Cancio LC, Barillo DJ, Kearns RD, et al. Guidelines for Burn Care Under Austere Conditions: Surgical and Nonsurgical Wound Management. J Burn Care Res. 2017;38(4):203-214. [5] Driscoll RR, Mann-Salinas EA, Boyer NL, Pamplin JC, Serio-Melvin ML, Salinas J, Borgman MA, Sheridan RL, Melvin JJ, Peterson WC, Graybill JC, Rizzo JA, King BT, Chung KK, Cancio LC, Renz EM, Stockinger ZT. Burn Care, Joint Trauma System Clinical Practice Guidelines, 2016; 12:1-33.  
**Acknowledgements:** The work is funded by the Naval Medical Research Command (NMRC) – Naval Advanced Medical Development (NAMD) program via the Medical Technology Enterprise Consortium (MTEC), award # W81XWH-20-9-0006.  
**Disclaimer:** This study has been conducted in compliance with the Animal Welfare Act, the implementing Animal Welfare Regulations, and the principles of the Guide for the Care and Use of Laboratory Animals.