

Complicated Colorectal Wounds: Case Series of Patients Treated with Transforming Powder Dressing

Theresa Pineda, BSN, RN, CWOCN; Carolyn Cintron, RN, BSN, CWOCN;
 Tammy Jensen Lichtman RN, BSN, CWON | AdventHealth System, Orlando, FL

Symposium on Advanced Wound Care (SAWC) Spring 2024 Meeting, Orlando, FL

INTRODUCTION

Colorectal post-operative wounds present some of the most challenging wounds to manage. Surgical site infections (SSI) occur in a range of 5-30% of cases, representing a costly complication associated with significant increases in postoperative morbidity.¹ While the standard of care typically involves leaving these wounds open to reduce the risk of SSI, such techniques impose additional disadvantages on patients. These include delayed wound closure, pain, and frequent and time-consuming dressing changes.¹

METHODOLOGY & MATERIALS

We present four complex colorectal surgical patients who were treated with Transforming Powder Dressing (TPD*) initially or after failing standard of care (SOC). TPD is a powder-based dressing comprised primarily of two biocompatible polymers (similar to those used in contact lenses). Upon hydration with saline, TPD granules aggregate to form a moist, oxygen-permeable barrier that covers and protects the wound from contamination, while facilitating the flow of excess exudate through vapor transportation. Once applied, TPD may be left in place for up to 30 days and be covered with simple, non-occlusive secondary dressings in areas of high friction or exudation. Additional powder is added ("topped off") as needed without requiring primary dressing changes. As the wound heals, TPD dries and flakes off.

DISCUSSION

All wounds healed without complications with the use of TPD. Nursing time and dressing change frequency were reduced compared to SOC. TPD provided a safe, efficient and less painful solution for the management of these complex colorectal surgical wounds.

REFERENCES

(1) Mullen MG, Hawkins RB, Johnston LE, Shah PM, Turrentine FE, Hedrick TL, Friel CM. Open Surgical Incisions After Colorectal Surgery Improve Quality Metrics, But Do Patients Benefit? Dis Colon Rectum. 2018 May;61(5):622-628. doi: 10.1097/DCR.0000000000001049. PMID: 29578920; PMCID: PMC5889337.

Acknowledgements: This poster was created in collaboration with Altrazeal Life Sciences Inc. All clinical cases and analyses were performed independently by the authors and no compensation was paid. For application instructions and risks of this device please refer to Altrazeal Instructions for Use. | EDU-0141

OUTCOMES

PATIENT 1

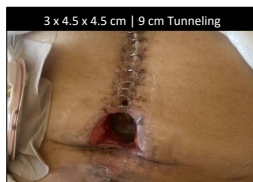History: 55 y/o male with recurrent colon cancer s/p SBR with resultant 60.75 cm³ abdominal wound and 9 cm tunnel

Challenge: NPWT was unavailable to patient post-discharge

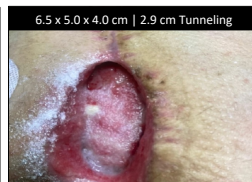Treatment: Weekly TPD applications/top-offs. Wife changed secondary dressing for break through drainage

Outcomes:

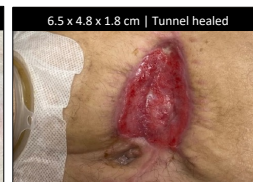- Tunnel (9 cm) healed in 6 weeks.
- Wound was 2cm³ (97% healed) after 18 weeks while on chemotherapy and immunotherapy and fully healed at 25 weeks.



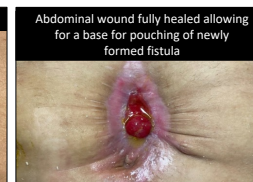Pre-TPD: Normal saline and damp to dry wound dressings



Day 14 Post-TPD: No s/s of infection, no enteric contents



Day 41: Epithelialization, improving endurance, return to work, initiated chemo



Day 171: Continued to maintain quality of life while receiving chemo and immuno therapy

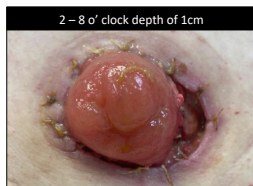
PATIENT 2

History: 62 y/o female with metastatic ovarian cancer underwent rectosigmoid resection / colostomy and developed mucocutaneous separation (MCS); no treatment prior to TPD

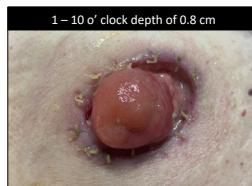
Treatment: TPD applied/topped-off post appliance changes (every 2 to four days)

Outcomes:

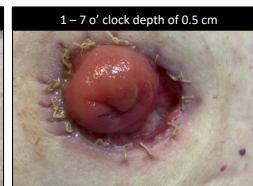
- MCS healed in 6 weeks



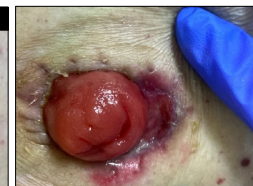Pre-TPD: Seropurulent drainage, cleansed with Vashe solution, applied TPD



Day 7: Mucocutaneous separation slightly larger. Continued with TPD weekly



Day 14: Mucocutaneous separation depth is more superficial. Wear-time is 5-7 days



Day 34: Mucocutaneous separation continues to heal. Weekly TPD application

PATIENT 3

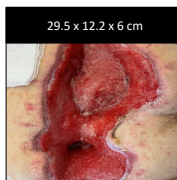History: 48 y/o female s/p transverse colostomy / partial colectomy / Stamm Gastrostomy developed enterocutaneous and enteroatmospheric fistulas and large 2,159.4 cm³ abdominal wound

Challenge: Failed NPWT (drainage obstructed machine)

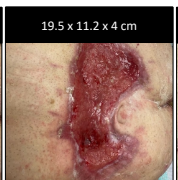TPD Treatment: TPD was applied/topped-off weekly to abdominal wound as indicated

Outcomes:

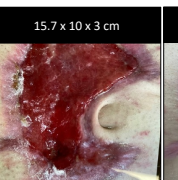
- Wound healed in 30 weeks



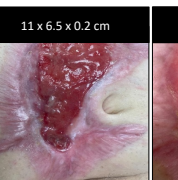
Day 0



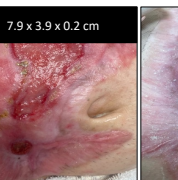
Day 83



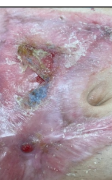Day 110



Day 181



Day 266: Closed



Day 302: TPD Discontinued

PATIENT 4

History: 41 y/o male with rectal cancer s/p robotic low anterior resection with diverting loop ileostomy c/b abdominal wound dehiscence (750 cm³ wound with 10 cm tunnel)

Challenge: NPWT was discontinued due to pain, fistula development and excessive bleeding

Treatment: Weekly TPD applications/top-offs

Outcomes:

- Wound was 0.4cm³ (99% healed) after 29 weeks when he was taken for additional surgery (not related to the wound).

