



VA



U.S. Department of Veterans Affairs

Symposium on Advanced Wound Care (SAWC) Spring 2025 Meeting, May 1 - 3 | Dallas, TX

Extended Wear Dressing in Acute Traumatic Wounds: Case Series from a Ukrainian Combat Hospital Shows Reduced Pain, Hospital Stay, and Dressing Changes

Rostyslav Bublii, MD, City Clinical Hospital #4 of Dnipro City Council, Ukraine; Susan Rolniak St. John, MSN, APRN-NP, Clinical Consultant, Altrazeal Life Sciences Inc.; Michael Samotowka, MD, FACS, Veterans Administration, Hospital Louis B Stokes, Cleveland, Ohio, USA

INTRODUCTION

Burns, open wounds, and penetrating shrapnel injuries from combat blasts result in immense pain and prolonged recovery, delaying soldiers' return to duty (RTD)¹. In Ukraine, hospitals are overwhelmed with a continuous influx of seriously wounded soldiers, facing over 30,000 new injuries each month². Effective wound management is crucial in this context. This case series evaluated the efficacy of a commercially available, shelf-stable, extended-wear transforming powder dressing (TPD*), recently introduced at a Ukrainian combat hospital for treating acute traumatic wounds. Conventional wound care products often necessitate multiple dressing changes daily or weekly, consuming significant medical resources, including time, personnel, and materials. In contrast, TPD offers an innovative solution that can stay in place for extended periods (up to 30 days), potentially easing the burden on medical facilities and personnel.

METHODOLOGY AND MATERIALS

Four male soldiers (ages 28-51) with different types of injuries were treated with TPD:

1. Shrapnel wound to the thigh complicated by hematoma and necrosis requiring surgical debridement
2. Mixed deep and superficial partial-thickness burns [6% total body surface area (TBSA)] on the back, neck, and arm
3. Penetrating wound to the buttock with embedded shrapnel
4. Embedded shrapnel wound to the arm requiring necrotomy

All patients received standard care with antibiotics, and TPD was applied in place of conventional dressings.

Upon hydration with wound exudate or saline, TPD aggregates to form a moist, oxygen-permeable barrier that protects the wound from contamination while allowing vapor transpiration of excess fluids. Simple secondary covers may be used in areas of high exudation of friction.

One of the key advantages of TPD is its ability to be topped off by simply sprinkling additional powder over the existing dressing, without the need for removing or changing the primary dressing layer. This feature makes it particularly useful in difficult to dress and painful wounds, where frequent dressing changes are typically required with conventional products. As the wound heals, TPD dries and flakes off.

References:

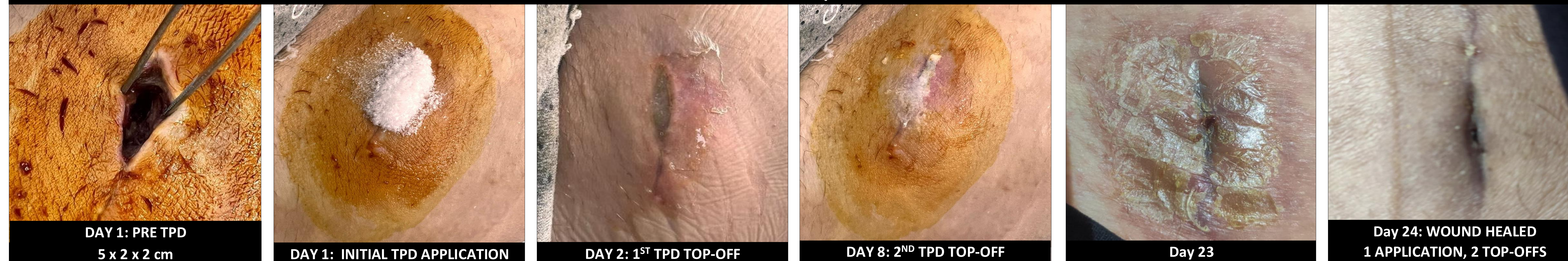
1. D'Souza EW, MacGregor AJ, Dougherty AL, Olson AS, Champion HR, Galarneau MR. Combat injury profiles among U.S. military personnel who survived serious wounds in Iraq and Afghanistan: A latent class analysis. *PLoS One*. 2022 Apr 6;17(4):e0266588. doi: 10.1371/journal.pone.0266588. PMID: 35385552; PMCID: PMC8985965.
2. <https://abcnews.go.com/International/hospital-sees-30-rise-wounded-ukrainian-soldiers-doctor/story?id=106197525>.

Acknowledgements: This poster was created in collaboration with Altrazeal Life Sciences Inc.(ALSI). All clinical cases and analyses were conducted independently by the authors, with no compensation received from ALSI. For application instructions and information on the risks associated with this device, please refer to the Altrazeal Instructions for Use.. | EDU-0190, Rev 03

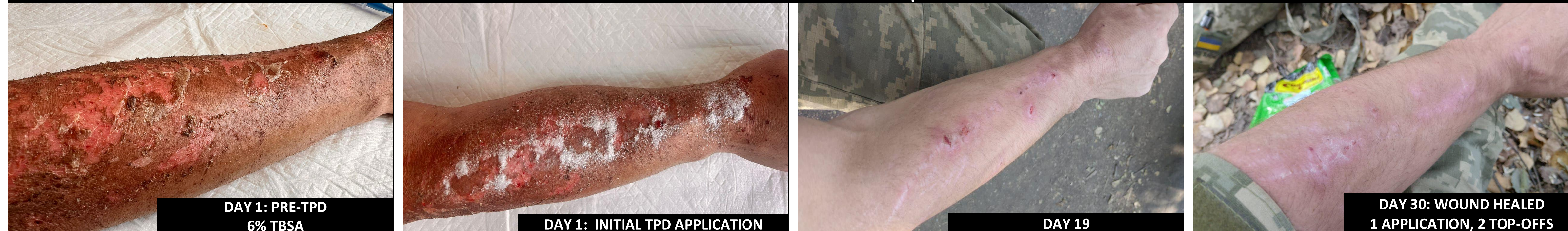RESULTS

All wounds progressed to complete healing, with no complications. TPD was successfully used by the surgical team and soldiers themselves during their recovery, including post hospital discharge. Implementation of TPD led to a significant decrease in pain, expected length of stay (LOS) and dressing changes for all soldiers, enabling faster RTD with one application and two top-offs for all wounds.

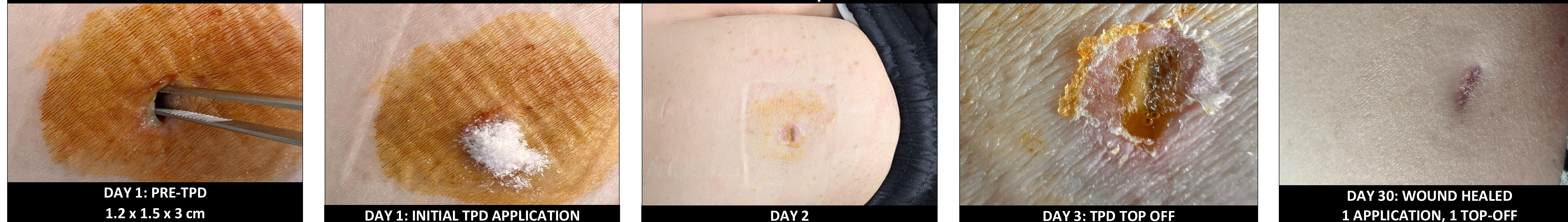SHRAPNEL WOUND | RTD: 7 DAYS



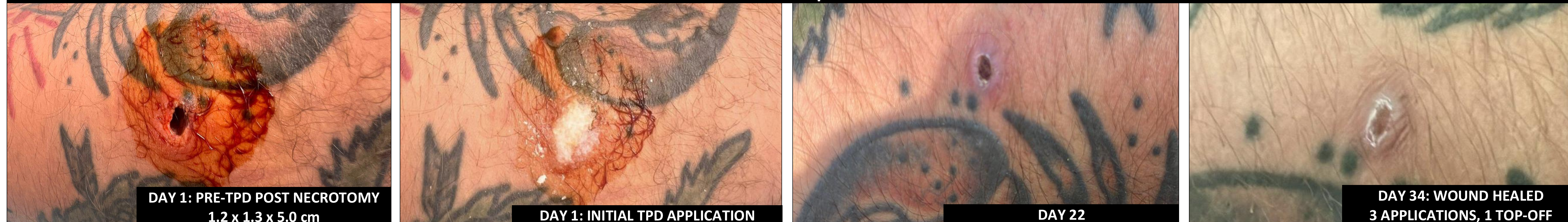SUPERFICIAL PARTIAL-THICKNESS BURNS | RTD: 13 DAYS



SHRAPNEL WOUND | RTD: 10 DAYS



SHRAPNEL WOUND | RTD: 11 DAYS



CONCLUSION

This case series suggests that TPD is a valuable option for managing acute traumatic wounds in high-volume combat settings or civilian settings with a shortage of medical personnel. By providing effective wound coverage, minimizing the need for frequent and painful dressing changes that may increase exposure to infection, and facilitating faster RTD, TPD can play a critical role in conserving medical resources and improving patient outcomes in challenging environments.

*Altrazeal Transforming Powder Dressing, USA